

NCCN Clinical Practice Guidelines in Oncology (NCCN Guidelines™)

Anal Carcinoma

Version 1.2012

NCCN.org

Continue



National
Comprehensive
Cancer
Network®

NCCN Guidelines™ Version 1.2012 Panel Members

Anal Carcinoma

[NCCN Guidelines Index](#)
[Anal Carcinoma Table of Contents](#)
[Discussion](#)

*Al B. Benson, III, MD/Chair †
Robert H. Lurie Comprehensive Cancer
Center of Northwestern University

J. Pablo Arnoletti, MD ¶
University of Alabama at Birmingham
Comprehensive Cancer Center

Tanios Bekaii-Saab, MD †
The Ohio State University Comprehensive
Cancer Center - James Cancer Hospital and
Solove Research Institute

Emily Chan, MD, PhD †
Vanderbilt-Ingram Cancer Center

Yi-Jen Chen, MD, PhD §
City of Hope Comprehensive Cancer Center

Michael A. Choti, MD, MBA ¶
The Sidney Kimmel Comprehensive Cancer
Center at Johns Hopkins

Harry S. Cooper, MD ≠
Fox Chase Cancer Center

Raza A. Dilawari, MD ¶
St. Jude Children's Research
Hospital/University of Tennessee Cancer
Institute

*Paul F. Engstrom, MD †
Fox Chase Cancer Center

Peter C. Enzinger, MD †
Dana-Farber/Brigham and Women's Cancer
Center

James W. Fleshman, Jr., MD ¶
Siteman Cancer Center at Barnes-Jewish
Hospital and Washington University School
of Medicine

Charles S. Fuchs, MD, MPH †
Dana-Farber/Brigham and Women's Cancer
Center

Jean L. Grem, MD †
UNMC Eppley Cancer Center at The Nebraska
Medical Center

James A. Knol, MD ¶
University of Michigan Comprehensive
Cancer Center

Lucille A. Leong, MD †
City of Hope Comprehensive Cancer Center

Edward Lin, MD †
Fred Hutchinson Cancer Research
Center/Seattle Cancer Care Alliance

Kilian Salerno May, MD §
Roswell Park Cancer Institute

Mary F. Mulcahy, MD ‡
Robert H. Lurie Comprehensive Cancer
Center of Northwestern University

Kate Murphy, BA ≠
Fight Colorectal Cancer

Eric Rohren, MD, PhD ϕ
The University of Texas MD Anderson Cancer
Center

David P. Ryan, MD †
Massachusetts General Hospital Cancer
Center

*Leonard Saltz, MD † ‡ ρ
Memorial Sloan-Kettering Cancer Center

Sunil Sharma, MD †
Huntsman Cancer Institute at the University
of Utah

David Shibata, MD ¶
H. Lee Moffitt Cancer Center and Research
Institute

John M. Skibber, MD ¶
The University of Texas MD Anderson Cancer
Center

William Small, Jr., MD §
Robert H. Lurie Comprehensive Cancer
Center of Northwestern University

Constantinos T. Sofocleous, MD, PhD ϕ
Memorial Sloan-Kettering Cancer Center

*Alan P. Venook, MD † ‡
UCSF Helen Diller Family Comprehensive
Cancer Center

Christopher Willett, MD §
Duke Cancer Institute

NCCN
Deborah Freedman-Cass, PhD
Kristina M. Gregory, RN, MSN, OCN

† Medical Oncology
§ Radiotherapy/Radiation oncology
¶ Surgery/Surgical oncology
≠ Pathology
‡ Hematology/Hematology Oncology
ρ Internal medicine
ϕ Diagnostic/Interventional Radiology
≠ Patient advocate
* Writing Committee Member

Continue

[NCCN Guidelines Panel Disclosures](#)



National
Comprehensive
Cancer
Network®

NCCN Guidelines™ Version 1.2012 Table of Contents

Anal Carcinoma

[NCCN Guidelines Index](#)
[Anal Carcinoma Table of Contents](#)
[Discussion](#)

[NCCN Anal Carcinoma Panel Members](#)

[Summary of the Guidelines Updates](#)

[Workup and Treatment - Anal canal cancer \(ANAL-1\)](#)

[Workup and Treatment - Anal margin lesions \(ANAL-2\)](#)

[Follow-up Therapy and Surveillance \(ANAL-3\)](#)

[Principles of Chemotherapy \(ANAL-A\)](#)

[Principles of Radiation Therapy \(ANAL-B\)](#)

[Staging \(ST-1\)](#)

Clinical Trials: The NCCN believes that the best management for any cancer patient is in a clinical trial. Participation in clinical trials is especially encouraged.

To find clinical trials online at NCCN member institutions, [click here: nccn.org/clinical_trials/physician.html](#)

NCCN Categories of Evidence and Consensus: All recommendations are Category 2A unless otherwise specified.

See [NCCN Categories of Evidence and Consensus](#)

The NCCN Guidelines™ are a statement of evidence and consensus of the authors regarding their views of currently accepted approaches to treatment. Any clinician seeking to apply or consult the NCCN Guidelines is expected to use independent medical judgment in the context of individual clinical circumstances to determine any patient's care or treatment. The National Comprehensive Cancer Network® (NCCN®) makes no representations or warranties of any kind regarding their content, use or application and disclaims any responsibility for their application or use in any way. The NCCN Guidelines are copyrighted by National Comprehensive Cancer Network®. All rights reserved. The NCCN Guidelines and the illustrations herein may not be reproduced in any form without the express written permission of NCCN. ©2010.



Summary of changes in the 1.2012 version of the Anal Carcinoma Guidelines from the 2.2011 version include:

ANAL-1

- Footnote “a” added defining anal canal cancer: “The superior border of the functional anal canal, separating it from the rectum, has been defined as the palpable upper border of the anal sphincter and puborectalis muscles of the anorectal ring. It is approximately 3 to 5 cm in length, and its inferior border starts at the anal verge, the lowermost edge of the sphincter muscles, corresponding to the introitus of the anal orifice.”
- The specific RT dosing removed from the treatment section, as this information is noted in the Principles of Radiation Therapy section. Previous footnote “e” also deleted, “Re-evaluate at 45 Gy, if persistent disease, consider increasing to 55-59 Gy.”
- Metastatic disease: local RT added as a treatment option with cisplatin-based chemotherapy.
- Footnote “h” modified by the addition of “Local control can be achieved with the use of RT.”

ANAL-2

- Footnote “i” added defining anal margin cancer: “The anal margin starts at the anal verge and includes the perianal skin over a 5- to 6-cm radius from the squamous mucocutaneous junction.”
- The specific RT dosing removed from the treatment section, as this information is noted in the Principles of Radiation Therapy section.
- Metastatic disease: local RT added as a treatment option with cisplatin-based chemotherapy.
- Footnote “h” modified by the addition of “Local control can be achieved with the use of RT.”

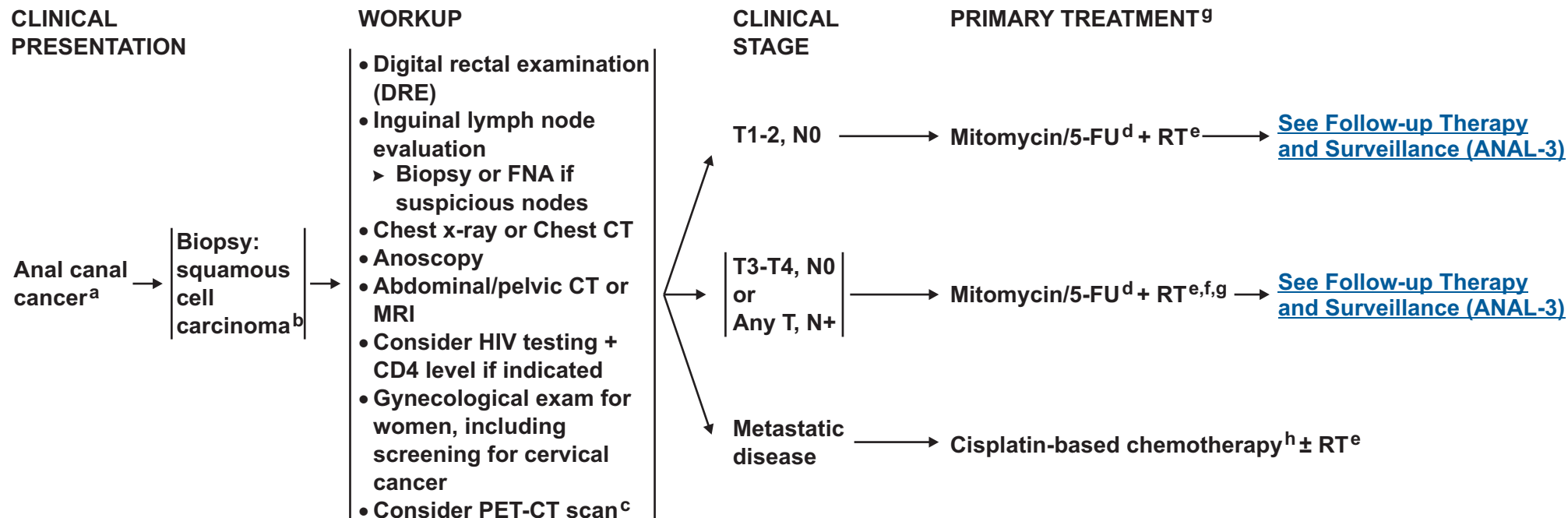
ANAL-B

- Bullet 1 modified: All patients should receive a minimum dose of 45 Gy in 25 fractions of 1.8 Gy over 5 weeks to the primary cancer *node positive cancer* with supervoltage radiation (photon energy of > 6 mV) ~~using anteroposterior-posteroanterior (AP-PA) or multifield techniques.~~
- Bullet 2, second sentence modified: The lateral border of AP fields includes the lateral inguinal nodes as determined from bony landmarks or imaging (computed tomography), ~~but lateral inguinal nodes are not routinely included in the PA fields to allow adequate sparing of the femoral heads. There should be attempts to reduce the dose to the femoral heads.~~
- Bullet 8, last sentence deleted: All male patients should be evaluated for erectile dysfunction and considered for early treatment intervention if necessary.



NCCN Guidelines™ Version 1.2012

Anal Carcinoma



^aThe superior border of the functional anal canal, separating it from the rectum, has been defined as the palpable upper border of the anal sphincter and puborectalis muscles of the anorectal ring. It is approximately 3 to 5 cm in length, and its inferior border starts at the anal verge, the lowermost edge of the sphincter muscles, corresponding to the introitus of the anal orifice.

^bFor melanoma histology, see the [NCCN Melanoma Guidelines](#), for adenocarcinoma, see the [NCCN Rectal Cancer Guidelines](#).

^cPET-CT scan does not replace a diagnostic CT. The routine use of a PET-CT scan for staging or treatment planning has not been validated.

^d[See Principles of Chemotherapy ANAL-A.](#)

Ajani JA, Winter KA, Gunderson LL, et al. Fluorouracil, mitomycin, and radiotherapy vs fluorouracil, cisplatin, and radiotherapy for carcinoma of the anal canal: a randomized controlled trial. In a randomized trial, the strategy of using neoadjuvant therapy with 5-FU + cisplatin followed by concurrent therapy with 5-FU + cisplatin + RT was not superior to 5-FU + mitomycin + RT.

^e[See Principles of Radiation Therapy ANAL-B.](#)

^fInclude bilateral inguinal/low pelvic nodal regions based upon estimated risk of inguinal involvement.

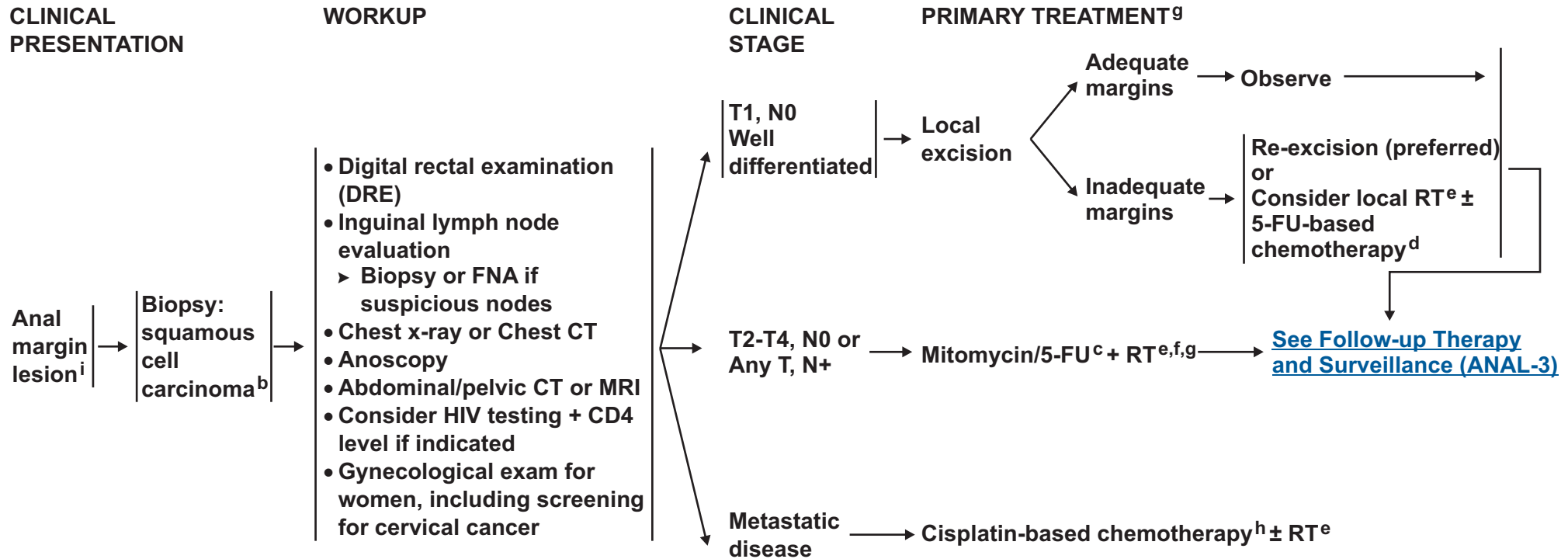
^gPatients with anal cancer as the first manifestation of HIV, may be treated with the same regimen as non-HIV patient. Patients with active HIV/AIDS-related complications or a history of complications (eg, malignancies, opportunistic infections) may not tolerate full-dose therapy or may not tolerate mitomycin and require dosage adjustment or treatment without mitomycin.

^hCisplatin/5-fluorouracil recommended for metastatic disease. If this regimen fails, no other regimens have shown to be effective.

[See Principles of Chemotherapy ANAL-A.](#) Local control can be achieved with the use of RT.

Note: All recommendations are category 2A unless otherwise indicated.

Clinical Trials: NCCN believes that the best management of any cancer patient is in a clinical trial. Participation in clinical trials is especially encouraged.



^bFor melanoma histology, see the [NCCN Melanoma Guidelines](#), for adenocarcinoma, see the [NCCN Rectal Cancer Guidelines](#).

^d[See Principles of Chemotherapy ANAL-A.](#)

Ajani JA, Winter KA, Gunderson LL, et al. Fluorouracil, mitomycin, and radiotherapy vs fluorouracil, cisplatin, and radiotherapy for carcinoma of the anal canal: a randomized controlled trial. JAMA 2008;299:1914. The strategy of using neoadjuvant therapy with 5-FU + cisplatin followed by concurrent therapy with 5-FU + cisplatin + RT was not superior to 5-FU + mitomycin + RT.

^e[See Principles of Radiation Therapy ANAL-B.](#)

^fInclude bilateral inguinal/low pelvic nodal regions based upon estimated risk of inguinal involvement.

⁹Patients with anal cancer as the first manifestation of HIV, may be treated with the same regimen as non-HIV patient. Patients with active HIV/AIDS-related complications or a history of complications (eg, malignancies, opportunistic infections) may not tolerate full-dose therapy or may not tolerate mitomycin and require dosage adjustment or treatment without mitomycin.

^hCisplatin/5-fluorouracil recommended for metastatic disease. If this regimen fails, no other regimens have shown to be effective.

[See Principles of Chemotherapy ANAL-A.](#) Local control can be achieved with the use of RT.

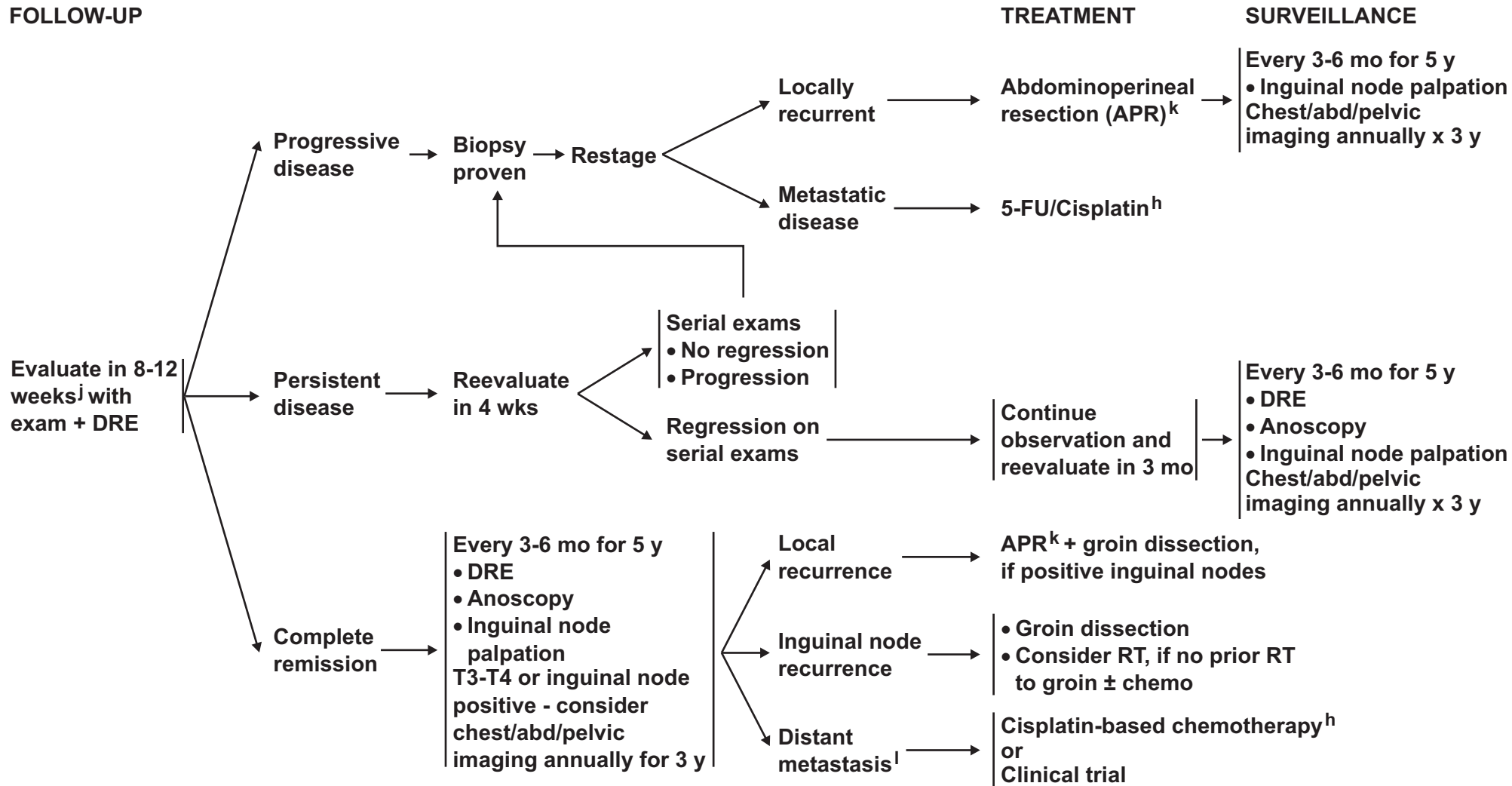
ⁱThe anal margin starts at the anal verge and includes the perianal skin over a 5- to 6-cm radius from the squamous mucocutaneous junction.

Note: All recommendations are category 2A unless otherwise indicated.

Clinical Trials: NCCN believes that the best management of any cancer patient is in a clinical trial. Participation in clinical trials is especially encouraged.



FOLLOW-UP



^hCisplatin/5-fluorouracil recommended for metastatic disease. If this regimen fails, no other regimens have shown to be effective.

[See Principles of Chemotherapy ANAL-A.](#)

^jIf patient with an initially tethered tumor returns 6 weeks post RT with a mobile but suspicious mass, consider biopsy.

^kConsider muscle flap reconstruction.

^lThere is no evidence supporting resection of metastatic disease.

Note: All recommendations are category 2A unless otherwise indicated.

Clinical Trials: NCCN believes that the best management of any cancer patient is in a clinical trial. Participation in clinical trials is especially encouraged.



National
Comprehensive
Cancer
Network®

NCCN Guidelines™ Version 1.2012

Anal Carcinoma

[NCCN Guidelines Index](#)
[Anal Carcinoma Table of Contents](#)
[Discussion](#)

PRINCIPLES OF CHEMOTHERAPY

Localized cancer

5-FU + Mitomycin + RT¹

5-FU 1000 mg/m²/d IV days 1-4 and 29-32

Mitomycin 10 mg/m² IV bolus days 1 and 29

Concurrent radiotherapy ([See ANAL-B](#))

Metastatic cancer

5-FU + Cisplatin²

5-FU 1000 mg/m²/d IV days 1-5

Cisplatin 100 mg/m² IV day 2

Repeat every 4 weeks

¹Ajani JA, Winter KA, Gunderson LL, et al. Fluorouracil, mitomycin, and radiotherapy vs fluorouracil, cisplatin, and radiotherapy for carcinoma of the anal canal: a randomized controlled trial. JAMA 2008;299:1914-1921. Copyright © (2008) American Medical Association. All rights reserved.

²Faivre C, Rougier P, Ducreux M, et al. 5-fluorouracil and cisplatin combination chemotherapy for metastatic squamous-cell anal cancer. Bull Cancer 1999;86:861-5.

Note: All recommendations are category 2A unless otherwise indicated.

Clinical Trials: NCCN believes that the best management of any cancer patient is in a clinical trial. Participation in clinical trials is especially encouraged.



PRINCIPLES OF RADIATION THERAPY¹

- **All patients should receive a minimum dose of 45 Gy in 25 fractions of 1.8 Gy over 5 weeks to the primary cancer node positive cancer with supervoltage radiation (photon energy of > 6 mV) multifield techniques.**
- **Initial radiation fields include the pelvis, anus, perineum, and inguinal nodes, with the superior field border at L5-S1 and the inferior border to include the anus with a minimum margin of 2.5 cm. around the anus and tumor. The lateral border of AP fields includes the lateral inguinal nodes as determined from bony landmarks or imaging. There should be attempts to reduce the dose to the femoral heads.**
- **After a dose of 30.6 Gy in 17 fractions, the superior field extent is reduced to the bottom of the sacroiliac joints and an additional 14.4 Gy is given in 8 fractions (total dose of 45 Gy in 25 fractions/5weeks), with additional field reduction off node-negative inguinal nodes after 36 Gy.**
- **For patients treated with an AP-PA rather than 4-field technique, an anterior electron boost (matched to the PA exit field) is used to bring the lateral inguinal region to the minimum dose of 36 Gy.**
- **For patients with T3, T4, node-positive disease or patients with T2 residual disease after 45 Gy, the intent is usually to deliver an additional boost of 9 to 14 Gy in 1.8 to 2 Gy fractions (total dose of 54-59 Gy in 30-32 fractions over 6.0-7.5 weeks).**
- **The target volume for boost field 2 is the original primary tumor volume/node plus a 2- to 2.5 cm. margin. Treatment field options include a multifield photon approach (AP-PA plus paired laterals, PA + laterals, or other) or a direct perineal boost with electrons or photons with the patient in lithotomy position.**
- **Intensity modulated radiation therapy in addition to three dimensional conformal radiation therapy may be used in the treatment of patients with anal cancer.²**
- **Side effect management:**
Female patients should be considered for vaginal dilators and instructed on the symptoms of vaginal stenosis.

¹Ajani JA, Winter KA, Gunderson LL, et al. Fluorouracil, mitomycin, and radiotherapy vs fluorouracil, cisplatin, and radiotherapy for carcinoma of the anal canal. JAMA 2008;299:1914-1921. Copyright © (2008) American Medical Association. All rights reserved.

²Myerson RJ, Garofolo MC, Naqa IE, et al. Elective clinical target volumes for conformal therapy in anorectal cancer: A Radiation Therapy Oncology Group Consensus Panel Contouring Atlas. Int J Radiat Oncol Biol Phys 2009;74:824-830.

Note: All recommendations are category 2A unless otherwise indicated.

Clinical Trials: NCCN believes that the best management of any cancer patient is in a clinical trial. Participation in clinical trials is especially encouraged.

**Table 1. DEFINITIONS OF TNM****Primary Tumor (T)**

TX	Primary tumor cannot be assessed
T0	No evidence of primary tumor
Tis	Carcinoma in situ (Bowen's disease, high-grade squamous intraepithelial lesion (HSIL), anal intraepithelial neoplasia II–III (AIN II–III))
T1	Tumor 2 cm or less in greatest dimension
T2	Tumor more than 2 cm but not more than 5 cm in greatest dimension
T3	Tumor more than 5 cm in greatest dimension
T4	Tumor of any size invades adjacent organ(s), e.g., vagina, urethra, bladder*

* Note: Direct invasion of the rectal wall, perirectal skin, subcutaneous tissue, or the sphincter muscle(s) is not classified as T4.

Regional Lymph Nodes (N)

NX	Regional lymph nodes cannot be assessed
N0	No regional lymph node metastasis
N1	Metastasis in perirectal lymph node(s)
N2	Metastasis in unilateral internal iliac and/or inguinal lymph node(s)
N3	Metastasis in perirectal and inguinal lymph nodes and/or bilateral internal iliac and/or inguinal lymph nodes

Distant Metastasis (M)

M0	No distant metastasis
M1	Distant metastasis

Table 2. ANATOMIC STAGE/PROGNOSTIC GROUPS

Stage	T	N	M
0	Tis	N0	M0
I	T1	N0	M0
II	T2	N0	M0
	T3	N0	M0
	T4	N0	M0
IIIA	T1	N1	M0
	T2	N1	M0
	T3	N1	M0
	T4	N0	M0
IIIB	T4	N1	M0
	Any T	N2	M0
	Any T	N3	M0
IV	Any T	Any N	M1

Used with the permission of the American Joint Committee on Cancer (AJCC), Chicago, Illinois. The original and primary source for this information is the AJCC Cancer Staging Manual, Seventh Edition (2010) published by Springer Science and Business Media LLC (SBM). (For complete information and data supporting the staging tables, visit www.springer.com.) Any citation or quotation of this material must be credited to the AJCC as its primary source. The inclusion of this information herein does not authorize any reuse or further distribution without the expressed, written permission of Springer SBM, on behalf of the AJCC.

Discussion

This discussion is being updated to correspond with the newly updated algorithm. Last updated 02/02/11

NCCN Categories of Evidence and Consensus

Category 1: Based upon high-level evidence, there is uniform NCCN consensus that the intervention is appropriate.

Category 2A: Based upon lower-level evidence, there is uniform NCCN consensus that the intervention is appropriate.

Category 2B: Based upon lower-level evidence, there is NCCN consensus that the intervention is appropriate.

Category 3: Based upon any level of evidence, there is major NCCN disagreement that the intervention is appropriate.

All recommendations are category 2A unless otherwise noted.

Overview

An estimated 5,260 new cases (2,000 men and 3,260 women) of anal cancer (involving the anus, anal canal, or the anorectum) will occur in the United States in 2010, accounting for approximately 1.9% of digestive system cancers.¹ It has been estimated that 720 deaths due to anal cancer will occur in the U.S. in 2010. Although considered to be a rare type of cancer, the incidence rate of invasive anal carcinoma in the U.S. increased by approximately 1.9-fold for men and 1.5-fold for women from the period of 1973-1979 to 1994-2000² (see section entitled Risk Factors, below).

This manuscript summarizes the NCCN clinical practice guidelines for managing squamous cell anal carcinoma which represents the most common histologic form of the disease. Other types of cancers occurring in the anal region, such as adenocarcinoma or melanoma,

are addressed in other NCCN guidelines (ie, anal adenocarcinoma and anal melanoma are managed according to the NCCN Rectal Cancer Guidelines and the NCCN Melanoma Guidelines, respectively). The recommendations in these guidelines are classified as category 2A except where noted, meaning that there is uniform NCCN consensus, based on lower-level evidence, that the recommendation is appropriate. The panel unanimously endorses patient participation in a clinical trial over standard or accepted therapy.

Risk Factors

Anal carcinoma has been associated with human papilloma virus (HPV) infection (anal-genital warts); a history of receptive anal intercourse or sexually transmitted disease; a history of cervical, vulvar, or vaginal cancer; immunosuppression after solid organ transplantation or human immunodeficiency virus (HIV) infection; hematologic malignancies; certain autoimmune disorders; and smoking.³⁻⁹ The association between anal carcinoma and persistent infection with a high-risk form of HPV (eg, HPV-16; HPV-18) is especially strong.^{4, 10, 11} For example, a study of tumor specimens from more than 60 pathology laboratories in Denmark and Sweden showed that high-risk HPV DNA was detected in 84% of anal cancer specimens, with HPV-16 detected in 73% of them. In contrast, high-risk HPV was not detected in any of the rectal cancer specimens analyzed.⁴ In addition, results of a systematic review of 35 peer-reviewed studies of anal cancer including detection of HPV DNA published up until July 2007 showed the prevalence of HPV-16/18 to be 72% in patients with invasive anal cancer.¹¹ Furthermore, suppression of the immune system by the use of immunosuppressive drugs or HIV infection is likely to facilitate persistence of HPV infection of the anal region.^{12, 13} In the HIV-infected population, the standardized incidence rate of anal carcinoma per 100,000 person-years in the U.S., estimated to be 19.0 in 1992-1995, increased to 78.2 during 2000-2003.¹⁴ This

result likely reflects both the survival benefits of highly active antiretroviral therapy (HAART) and the lack of an impact of HAART on the progression of anal cancer precursors.

Anatomy/Histology

The anal region is comprised of the anal canal and the anal margin, dividing anal cancers into 2 categories. The anal canal is the more proximal portion of the anal region. Various definitions of the anal canal exist (eg, functional/surgical; anatomic; and histological) that are based on particular physical/anatomic landmarks or histological characteristics. The functional anal canal is defined by the sphincter muscles. The superior border of the functional anal canal, separating it from the rectum, has been defined as the palpable upper border of the anal sphincter and puborectalis muscles of the anorectal ring. It is approximately 3 to 5 cm in length, and its inferior border starts at the anal verge, the lowermost edge of the sphincter muscles, corresponding to the introitus of the anal orifice.^{6, 15, 16} This definition is primarily used in the radical surgical treatment of anal cancer. In describing anal cancers, the histologic characteristics of the mucosal lining of the anal region form a more useful definition.¹⁷ The mucosa of the anal canal is predominantly formed by squamous epithelium, in contrast to the mucosa of the rectum which is lined with glandular epithelium.^{6, 15} The most superior aspect of the anal canal is a 1- to 2-cm zone between the anal and rectal epithelium which has rectal, urothelial, and squamous histologic characteristics.^{6, 15} The most inferior aspect of the anal canal, approximately at the anal verge, corresponds to the area where the mucosa lined with modified squamous epithelium transitions to an epidermis-lined anal margin. The anal margin starts at the anal verge and includes the perianal skin over a 5- to 6-cm radius from the squamous mucocutaneous junction.^{15, 18} It is covered by epidermis, not mucosa.⁶

Pathology

Most primary cancers of the anal canal are of squamous cell histology.^{15, 17} The second edition of the World Health Organization (WHO) classification system of anal carcinoma designated all squamous cell carcinoma variants of the anal canal as cloacogenic and identified subtypes as large-cell keratinizing, large-cell non-keratinizing (transitional), or basaloid.¹⁹ It has been reported that squamous cell cancers in the more proximal region of the anal canal are more likely to be non-keratinizing and less differentiated.⁶ However, the terms cloacogenic, transitional, keratinizing, and basaloid were removed from the 3rd and 4th editions of the WHO classification system^{20, 21} of anal canal carcinoma, and all subtypes have been included under a single generic heading of squamous cell carcinoma.^{18, 20} Reasons for this change include the following: both cloacogenic (which is sometimes used interchangeably with the term basaloid) and transitional tumors are now considered to be non-keratinizing tumors; it has been reported that both keratinizing and non-keratinizing tumors have a similar natural history and prognosis²⁰; and a mixture of cell types frequently characterize histologic specimens of squamous cell carcinomas of the anal canal.^{15, 20, 22} No distinction between squamous anal canal tumors on the basis of cell type has been made in the guidelines. Other less common anal canal tumors, not addressed in these guidelines, include adenocarcinomas in the rectal mucosa or the anal glands, small cell (anaplastic) carcinoma, undifferentiated cancers, and melanomas.¹⁵

Squamous cell carcinomas of the anal margin are more likely than those of the anal canal to be well-differentiated and keratinizing large-cell types,²³ but they are not characterized in the guidelines according to cell type. The presence of skin appendages (eg, hair follicles or sweat glands) in anal margin tumors can distinguish them from anal canal tumors. However, it is not always possible to distinguish between

anal canal and anal margin squamous cell carcinoma since tumors can involve both areas.

Lymph drainage of anal cancer tumors is dependent on the location of the tumor in the anal region: cancers in the perianal skin and the region of the anal canal distal to the dentate line drain mainly to the superficial inguinal nodes; lymph drainage at and proximal to the dentate line is directed toward the anorectal, perirectal, and paravertebral nodes and to some of the nodes of the internal iliac system; more proximal cancers drain to perirectal nodes and to nodes of the inferior mesenteric system.^{15, 18} Therefore, distal anal cancers present with a higher incidence of inguinal node metastasis, although the lymphatic drainage systems throughout the anal canal are not isolated from each other.¹⁵

Staging

The TNM staging system for anal canal cancer developed by the American Joint Committee on Cancer (AJCC) is detailed in the guidelines.¹⁸ Since current recommendations for the primary treatment of anal canal cancer do not involve a surgical excision, most tumors are staged clinically with an emphasis on the size of the primary tumor as determined by direct examination and microscopic confirmation.¹⁸ A tumor biopsy is required. Rectal ultrasound to determine depth of tumor invasion is not used in the staging of anal cancer (see Clinical Presentation/Evaluation, below).

In the past, these guidelines have used the AJCC TNM skin cancer system for the staging of anal margin cancer since the 2 types of cancers have a similar biology. However, the latest addition of the AJCC Cancer Staging Manual made substantial changes to the cutaneous squamous cell carcinoma stagings,¹⁸ making them much less appropriate for the staging of cancers of the anal margin.

Furthermore, many anal margin cancers have involvement of the anal canal or have high-grade, pre-cancerous lesions in the anal canal. It is important to look for such anal canal involvement, particularly if conservative management (simple excision) is being contemplated. Many patients, particularly HIV-positive ones, could be significantly under-treated. For these reasons, the guidelines now use the anal canal staging system for both tumors of the anal canal and of the anal margin.

Lymph node staging is based on location of involved nodes in the staging of anal canal cancer: N1 designates metastasis in 1 or more perirectal nodes; N2 represents metastasis in unilateral internal iliac nodes and/or inguinal node(s); and N3 designates metastasis in perirectal and inguinal nodes and/or bilateral internal iliac and/or inguinal nodes.¹⁸ However, initial therapy of anal cancer does not typically involve surgery, and the true lymph node status may not be determined accurately by clinical and radiologic evaluation. Fine needle aspiration (FNA) biopsy of inguinal nodes is recommended if tumor metastasis to these nodes is suspected.

The prognosis of anal carcinoma is related to the size of the primary tumor and the presence of lymph node metastases.⁶ According to the Surveillance, Epidemiology, and End Results (SEER) database,²⁴ between 1999 and 2006, 50% of anal carcinomas were localized at initial diagnosis; these patients had an 80% 5-year survival rate. Approximately 29% of patients with anal carcinomas already had spread to regional lymph nodes at diagnosis; these patients had a 60% 5-year survival rate. The 12% of patients presenting with distant metastasis demonstrated a 30.5% survival rate.²⁴ In a series of patients with anal cancer who underwent an abdominoperineal resection (APR), it was noted that pelvic nodal metastases were often under 0.5 cm,²⁵ suggesting that routine radiological evaluation with CT and PET scan

may not be reliable in the determination of lymph nodal involvement. In a retrospective study of 270 patients treated for anal canal cancer with radiation therapy (RT) between 1980 and 1996, synchronous inguinal node metastasis was observed in 6.4% of patients with tumors staged as T1 or T2, and in 16% of patients with T3 or T4 tumors.²⁶ In patients with N2-3 disease, survival was related to T-stage rather than nodal involvement with respective 5-year survival rates of 72.7% and 39.9% for patients with T1-T2 and T3-T4 tumors; however, the number of patients involved in this analysis was small.²⁶

Management of Anal Carcinoma

Clinical Presentation/Evaluation

Approximately 45% of patients with anal carcinoma present with rectal bleeding, while approximately 30% have either pain or the sensation of a rectal mass.⁶ Following confirmation of squamous cell carcinoma by biopsy, the recommendations of the NCCN Anal Carcinoma Guidelines panel for the clinical evaluation of patients with suspected anal canal or anal margin cancer are the same, with the exception of consideration of positron emission tomography (PET)/CT scan for tumors of the anal canal. The panel recommends a thorough examination/evaluation, including a careful digital rectal examination (DRE), palpation of the inguinal lymph nodes, and an anoscopic examination with biopsy or fine needle aspiration (FNA) of suspicious lesions. Assessment of T stage is primarily performed through clinical examination. Assessment of inguinal lymph node involvement for either anal margin or anal canal cancer is performed by FNA biopsy and/or excisional biopsy of nodes found to be enlarged by either clinical or radiological examination. Evaluation of pelvic lymph nodes with computed tomography (CT) or magnetic resonance imaging (MRI) of the pelvis is also recommended. These methods can also provide information on whether tumor involves other abdominal/pelvic organs. Since veins of the anal region are part

of the venous network associated with systemic circulation,¹⁵ chest x-ray or chest CT scan is performed to evaluate for pulmonary metastasis. PET/CT scanning has been reported to be useful in the evaluation of pelvic nodes, even in patients with anal canal cancer who have normal-sized lymph nodes on CT imaging²⁷⁻²⁹; however the panel does not consider PET/CT to be a replacement for a diagnostic CT. Furthermore, the panel noted that the routine use of a PET/CT scan for staging or treatment planning has not been validated. HIV testing and measurement of CD4 level is suggested as the risk of anal carcinoma has been reported to be higher in HIV-positive patients.⁸ Gynecological exam, including cervical cancer screening, is suggested for female patients due to the association of anal cancer and HPV.⁴

Primary Treatment of Anal Carcinoma

In the past, patients with invasive anal carcinoma were routinely treated with an abdominoperineal resection (APR); however, local recurrence rates were high, 5-year survival was only 40% to 70%, and the morbidity with a permanent colostomy was considerable.⁶ Currently, concurrent chemoradiation (chemoRT) is the recommended primary treatment for patients with non-metastatic anal canal cancer or with anal margin cancer characterized as T2-T4,N0 or node-positive. Well-differentiated anal margin lesions characterized as T1,N0 can be treated with margin-negative local excision alone. If adequate margins cannot be achieved, local RT with or without 5-FU-based chemotherapy can be considered. Metastatic disease is treated with cisplatin-based chemotherapy. If this regimen fails, no other regimens have been shown to be effective.

In 1974, Nigro and coworkers observed complete tumor regression in some patients with anal carcinoma treated with preoperative 5-fluorouracil (5-FU)-based concurrent chemoRT including either

mitomycin or porfiromycin, suggesting that it might be possible to cure anal carcinoma without surgery and permanent colostomy.³⁰ Subsequent nonrandomized studies using similar regimens and varied doses of chemotherapy and radiation provided support for this conclusion.^{31, 32} Results of randomized trials evaluating the efficacy and safety of administering chemotherapy with RT support the use of combined modality therapy in the treatment of anal cancer.⁹ Results from a phase III study from the European Organization for Research and Treatment of Cancer (EORTC) comparing the use of chemoRT (5-FU plus mitomycin) and RT alone in the treatment of anal carcinoma showed that patients in the chemoRT arm had an 18% higher rate of locoregional control at 5 years and a 32% longer colostomy-free interval.³³ The United Kingdom Coordinating Committee on Cancer Research (UKCCCR) randomized trial confirmed that chemoRT with 5-FU and mitomycin was more effective in controlling local disease than RT alone (relative risk=0.54, 95% CI, 0.42-0.69; P<0.0001), although no significant differences in overall survival were observed.³⁴ A recently published follow-up on these patients demonstrates that a clear benefit of chemoradiation remains after 13 years.³⁵

A number of studies have addressed the efficacy and safety of specific chemoRT regimens (involving chemotherapy regimens containing 1 or 2 agents) used in the treatment of anal carcinoma.^{33, 34, 36} In a phase III Intergroup study,³⁶ patients receiving chemoRT with the combination of 5-FU and mitomycin had a lower colostomy rate (9% versus 22%; P = 0.002) and a higher disease-free survival (73% vs 51%; P = 0.0003) compared with patients receiving chemoRT with 5-FU alone, indicating that mitomycin is an important component of chemoRT in the treatment of anal carcinoma. Survival rate at 4 years was the same for the 2 groups reflecting the ability to salvage recurrent patients with additional chemoradiation or an APR. Cisplatin as a substitute for 5-FU was

evaluated in a phase II trial, and results suggested that cisplatin-containing and 5-FU-containing chemoRT were comparable.³⁷ Use of 5-FU-based chemoRT combined with either mitomycin or cisplatin in the treatment of patients with anal carcinoma was investigated in the randomized phase III Intergroup Radiation Therapy Oncology Group (RTOG) 98-11 trial.³⁸ In this study, 682 patients were randomly assigned to receive either neoadjuvant 5-FU plus cisplatin for 2 cycles followed by concurrent chemoRT with 5-FU and cisplatin, or concurrent chemoRT with 5-FU and mitomycin. No significant differences were observed in the primary endpoint, disease-free survival (DFS), between the cisplatin group and the mitomycin group (54% vs. 60%; P=0.17), or in 5-year overall survival (70% vs. 75%; P=0.10). However, the colostomy rate was significantly higher in the group receiving cisplatin compared to the mitomycin-containing arm (19% vs.10%; P=0.02).³⁸

Since the 2 treatment arms in the RTOG 98-11 trial differed with respect to use of either cisplatin or mitomycin in concurrent chemoRT as well as inclusion of neoadjuvant chemotherapy in the cisplatin-containing arm of the trial, it is not presently possible to attribute the increased rate of colostomy to the substitution of cisplatin for mitomycin or to the use of induction chemotherapy.^{39, 40} A secondary combined multivariate analysis of the 2 arms of this trial showed that a pretreatment tumor size of >5 cm was predictive of an increased likelihood of colostomy.⁴¹ A summary of some of clinical trials involving patients with anal cancer has been presented.³⁹

Results from the phase III UK ACT II trial, the largest trial ever conducted in patients with anal cancer, were presented in 2009.⁴² In this study, over 900 patients with newly diagnosed anal cancer were randomly assigned to primary treatment with either 5-FU/mitomycin or 5-FU/cisplatin with radiotherapy. A continuous course (ie, no treatment gap) of radiation of 50.4 Gy was administered in both arms, and

patients in each arm were further randomized to receive 2 cycles of maintenance therapy with 5-FU and cisplatin or no maintenance therapy. At a median follow-up of 3 years, no differences were observed in the primary endpoint of complete response rate in either arm for the chemoRT comparison or in the primary endpoint of recurrence-free survival for the comparison of maintenance therapy versus no maintenance therapy. In addition, a secondary endpoint, colostomy, did not show differences based on the chemotherapeutic components of chemoRT.⁴² These results demonstrate that replacement of mitomycin with cisplatin in chemoRT does not increase the rate of complete response nor does administration of maintenance therapy decrease the rate of disease recurrence following primary treatment with chemoRT in patients with anal cancer.

The optimal dose and schedule of RT for anal carcinoma also continues to be explored, in addition to the schedule of chemotherapy relative to RT. Most studies have delivered 5-FU as a protracted 96 to 120 hour infusion during the first and fifth weeks of RT, and bolus injection of mitomycin is typically given on the first or second day of the 5-FU infusion.¹⁵ The effects of RT dose and RT schedule have been evaluated in a number of nonrandomized studies. In one study of patients with early-stage (T1 or Tis) anal canal cancer, most patients were effectively treated with RT doses of 40-50 Gy for Tis lesions and 50-60 Gy for T1 lesions.⁴³ In another study in which the majority of patients had stage II/III anal canal cancer, local control of disease was higher in patients who received RT doses greater than 50 Gy than in those who received lower doses (86.5% vs. 34%, $p=0.012$).⁴⁴ In a third study, patients with T3, T4 or lymph node-positive tumors, RT doses of ≥ 54 Gy administered with limited treatment breaks (less than 60 days) were associated with increased local control.⁴⁵

There is evidence that treatment interruptions (ie, gaps), either planned or required by treatment-related toxicity, can compromise the effectiveness of treatment.²⁸ In the phase II RTOG 92-08 trial, a planned 2-week treatment break in the delivery of chemoRT to patients with anal cancer was associated with increased local regional failure rates and lower colostomy-free survival rates when compared to patients who only had treatment breaks for severe skin toxicity,⁴⁶ although the trial was not designed for that particular comparison. In addition, the absence of a planned treatment break in the ACT II trial was considered to be at least partially responsible for the high relapse-free survival rates (75% at 3 years) observed in that study.⁴² Although results of other studies have also supported the benefit of delivery of chemoRT over shorter time periods,⁴⁷⁻⁴⁹ treatment breaks in the delivery of chemoRT are required in up to 80% of patients⁴⁹ since chemoRT-related toxicities are common. For example, it has been reported that one-third of patients receiving primary chemoRT for anal carcinoma at RT doses of 30 Gy in 3 weeks develop acute anoproctitis and perineal dermatitis, increasing to one-half to two-thirds of patients when RT doses of 54-60 Gy are administered in 6 to 7 weeks.¹⁵ Some of the reported late side effects of chemoRT include urgency and increased frequency of defecation, chronic perineal dermatitis, dyspareunia, and impotence.^{50, 51} In some cases, severe late RT complications, such as anal ulcers, stenosis, and necrosis, may necessitate surgery involving colostomy.⁵¹ In addition, results from a retrospective cohort study of data from the Surveillance, Epidemiology, and End Results (SEER) registry showed the risk of subsequent pelvic fracture to be 3-fold higher in older women undergoing radiation therapy for anal cancer compared with older women with anal cancer who did not receive radiation therapy.⁵²

There is an increasing body of literature suggesting that toxicity can be reduced with advanced radiation delivery techniques.^{28, 53-57} Intensity modulated radiation therapy (IMRT) utilizes detailed beam shaping to target specific volumes and limit the exposure of normal tissue.⁵⁷ Multiple pilot studies have demonstrated reduced toxicity while maintaining local control using IMRT. For example, in a cross-study comparison of a multicenter study of 53 patients with anal cancer treated with concurrent 5-FU/mitomycin C chemotherapy and IMRT compared to patients in the 5-FU/mitomycin C arm of the randomized RTOG 98-11 study involving use of conventional 3-D radiation therapy, the rates of grade 3/4 dermatologic toxicity were 38%/0% for IMRT-treated patients and 43%/5% for those undergoing conventional RT.^{38, 57} No decrease in treatment effectiveness or local control rates was observed with use of IMRT, although the small sample size and short duration of follow-up limit the conclusions drawn from such a comparison. Early reports of ongoing IMRT studies (eg, RTOG-0529) show promising results.^{58, 59} Its use requires expertise and careful target design to avoid reduction in local control by so-called “marginal-miss”.²⁸ The clinical target volumes for anal cancer used in the RTOG -0529 trial have been described in detail.⁶⁰ Also see http://atc.wustl.edu/protocols/rtog-closed/0529/ANAL_Ca_CTVs_5-21-07_Final.pdf for more details of the contouring atlas defined by RTOG.

As discussed above (see Risk Factors), patients with HIV/AIDS have been reported to be at increased risk of anal carcinoma.^{8, 9} Although most studies evaluating outcomes of patients with HIV/AIDS treated with chemoRT for anal carcinoma are retrospective,⁹ there is evidence to indicate that patients with anal carcinoma as the first manifestation of HIV/AIDS (especially those with a CD4 count of $\geq 200/\text{mm}^3$) may be treated with the same regimen as non-HIV patients.^{61, 62} Furthermore, in a recent retrospective cohort study of 1,184 veterans (15% of whom

tested positive for HIV) diagnosed with squamous cell carcinoma of the anus between 1998 and 2004, no differences with respect to receipt of treatment or 2-year survival rates were observed when the group of patients infected with HIV was compared with the group of patients testing negative for HIV.⁶³ This conclusion was supported by a study of 36 consecutive patients with anal cancer including 19 immunocompetent and 17 immunodeficient (14 HIV-positive) patients that showed no differences in the efficacy or toxicity of chemoRT.⁶⁴ In contrast, a recent cohort comparison of 40 HIV-positive patients with 81 HIV-negative patients with anal canal cancer found local relapse rates to be 4 times higher in the HIV-positive group (62% vs. 13%) at 3 years and found significantly higher rates of severe acute skin toxicity for patients infected with HIV.⁶⁵ However, no differences in rates of complete response or 5-year overall survival were observed between the 2 groups in that study. It is unclear whether increased compliance with HAART is associated with better outcomes following chemoRT for anal carcinoma.^{9, 66} Patients with active HIV/AIDS-related complications or a history of complications (eg, malignancies, opportunistic infections) may not tolerate full-dose therapy and may require dosage adjustment.

Recommendations for the Primary Treatment of Anal Canal Cancer

Anal canal cancer is treated with chemoRT (5-FU/mitomycin plus RT) as the primary treatment option. Recommendations regarding RT doses follow those used in the RTOG 98-11 trial.³⁸ All patients should receive a minimum RT dose of 45 Gy to the primary cancer. The recommended initial RT dose is 30.6 Gy to the pelvis, anus, perineum, and inguinal nodes. Field reduction off the superior field border and node-negative inguinal nodes is recommended after delivery of 30.6 Gy and 36 Gy, respectively. Patients with disease clinically staged as node-positive T3-T4, or with T2 residual disease after 45 Gy should receive an additional boost of 9-14 Gy. To manage side effects of radiation therapy, female patients should be considered for vaginal

dilators and should be instructed on the symptoms of vaginal stenosis. Male patients should be evaluated for erectile dysfunction and considered for early treatment intervention. The consensus of the panel is that IMRT may be used in place of 3-D conformal RT in the treatment of anal carcinoma.⁶⁰ Two cycles of 5-FU/mitomycin to be delivered during the first and fifth week of RT are recommended. Cisplatin-based chemotherapy is recommended to treat metastatic disease⁶⁷ (see Recommendations for the Treatment of Locally Recurrent/Metastatic Disease (Anal Canal/Margin Cancer)).

Recommendations for the Primary Treatment of Anal Margin Cancer

Anal margin lesions can be treated with either local excision or chemoRT depending on the clinical stage. Primary treatment for patients with T1,N0 well-differentiated anal margin cancers is by local excision with adequate margins. If the margins are not adequate, re-excision is the preferred treatment option. Local RT with or without 5-FU-based chemotherapy can be considered as an alternative treatment option when surgical margins are inadequate. T2 to T4 anal margin cancers and node-positive anal margin cancers of any T level are treated with mitomycin/5-FU plus RT (with doses and scheduling as described for anal canal cancers, above). Inclusion of bilateral inguinal/low pelvic nodal regions in the RT field should be considered for more advanced cancers. Cisplatin-based chemotherapy is recommended to treat metastatic disease⁶⁷ (see Recommendations for the Treatment of Locally Recurrent/Metastatic Disease (Anal Canal/Margin Cancer below)).

Follow-up and Surveillance Following Primary Treatment

Following primary treatment, the surveillance and follow-up treatment recommendations for anal margin and anal canal cancer are the same. Patients are re-evaluated by DRE between 8 and 12 weeks after completion of primary treatment with chemoRT. Following re-

evaluation, patients are classified according to whether they have a complete remission of disease, persistent disease, or progressive disease. Although a clinical assessment of progressive disease requires histologic confirmation, patients can be classified as having a complete remission without biopsy verification if clinical evidence of disease is absent. The panel recommends that these patients should undergo evaluation every 3 to 6 months for 5 years, including DRE, anoscopic evaluation, and inguinal node palpation. Chest, abdominal, and pelvic imaging should be considered annually for 3 years for patients who initially had locally advanced disease (ie, T3/T4 tumor) or node-positive cancers. Patients with persistent disease but without evidence of progression may be managed with close follow-up (in 4 weeks) to see if further regression occurs. If no regression of disease is observed on serial examination or if progression of disease occurs, further intensive treatment is indicated (see Treatment of Progressive/Recurrent/Metastatic Anal Carcinoma, below). Patients who show evidence of disease regression should be re-evaluated clinically in 3 months and every 3 to 6 months thereafter for 5 years, including DRE, anoscopic evaluation, and inguinal node palpation. Chest, abdominal, and pelvic imaging is recommended annually for 3 years for patients with slow regression.

Treatment of Progressive/Recurrent/Metastatic Anal Carcinoma

Despite the effectiveness of chemoRT in the primary treatment of anal carcinoma, rates of locoregional failure of 10-30% have been reported,⁶⁸ and radical salvage surgery with an APR has been the treatment of choice for these patients.⁶⁹ Some of the disease characteristics that have been associated with higher recurrence rates following chemoRT include higher T stage and higher N stage.⁷⁰ In studies involving a minimum of 25 patients undergoing a salvage APR for anal carcinoma, 5-year survival rates of 39%-64% were observed,

although complication rates were reported to be high in some of these studies.^{68, 69, 71-73} Factors associated with worse prognosis following salvage APR include an initial presentation of node-positive disease and RT doses <55 Gy used in the treatment of primary disease.⁶⁹ It has been shown that for patients undergoing an APR that was preceded by RT, closure of the perineal wound using rectum abdominus myocutaneous flap reconstruction resulted in decreased perineal wound complications.⁷⁴

It has been reported that the most common sites of metastasis outside of the pelvis include the liver, lung, and extrapelvic lymph nodes.⁷⁵ Since anal carcinoma is a rare cancer and only 10%-20% of patients with anal carcinoma present with extrapelvic metastatic disease,⁷⁵ only limited data are available on this population of patients. Despite this fact, there is some evidence to indicate that chemotherapy with a fluoropyrimidine-based regimen plus cisplatin has some benefit in patients with metastatic anal carcinoma.^{67, 75-77}

Recommendations for the Treatment of Progressive Disease (Anal Canal/Margin Cancer)

Evidence of progression found on DRE should be followed by biopsy as well as restaging with CT and/or PET imaging. Patients with biopsy-proven locally progressive disease are candidates for an APR. Muscle flap reconstruction of the perineum should be considered because of the extensive previous RT to the area. These patients should be re-evaluated every 3 to 6 months for 5 years, including clinical evaluation of nodal metastasis (ie, inguinal node palpation). In addition, it is recommended that these patients undergo annual imaging of the chest, abdomen, and pelvis for 3 years. The recommended treatment for patients with metastatic disease is 5-FU/cisplatin chemotherapy. There is no evidence supporting resection of metastatic disease.

Recommendations for the Treatment of Locally Recurrent/Metastatic Disease Following Complete Remission (Anal Canal/Margin Cancer)

Patients who are in complete remission should be evaluated every 3 to 6 months for 5 years as described (see Follow-up and Surveillance Following Primary Treatment). Treatment recommendations for patients who develop a local recurrence include an APR; muscle flap reconstruction of the perineum should be considered. Inguinal node dissection is reserved for recurrence in that area, and can be performed without an APR in cases where recurrence is limited to the inguinal nodes. Patients who develop inguinal node metastasis who do not undergo an APR can be considered for RT to the groin with or without chemotherapy, if no prior RT to the groin was given. Treatment recommendations for patients who develop a distant metastasis should be individualized, and local treatment, as described above, could be considered for the locally-symptomatic patient. There is no evidence supporting resection of metastatic disease. Treatment recommendations for patients with metastatic anal carcinoma include platinum-based chemotherapy or enrollment in a clinical trial. Currently, no other regimens have been shown to be effective in these patients following failure of 5-FU/cisplatin.

Summary

The NCCN Anal Carcinoma Guidelines panel believes that a multidisciplinary approach, including physicians from gastroenterology, medical oncology, surgical oncology, radiation oncology, and radiology, is necessary for treating patients with anal carcinoma. Recommendations for the primary treatment of anal margin cancer and anal canal cancer are very similar and include 5-FU/mitomycin-based RT, although small, well-differentiated anal margin lesions can be treated with margin-negative local excision alone. Follow-up clinical evaluations are recommended for all patients with anal carcinoma since



salvage is possible. Patients with biopsy-proven evidence of locoregional progressive disease following primary treatment should undergo an APR. Following complete remission of disease, patients with a local recurrence should be treated with an APR with a groin dissection if there is clinical evidence of inguinal nodal metastasis, and patients with a regional recurrence in the inguinal nodes can be treated with an inguinal node dissection, with consideration of RT with or without chemotherapy, if no prior RT to the groin was given. Patients with evidence of extrapelvic metastatic disease should be treated with cisplatin-based chemotherapy or enrolled in a clinical trial. The panel endorses the concept that treating patients in a clinical trial has priority over standard or accepted therapy.

Discussion
update in
progress

References

1. Jemal A, Siegel R, Xu J, Ward E. Cancer statistics, 2010. *CA Cancer J Clin* 2010;60:277-300. Available at: <http://caonline.amcancersoc.org/cgi/content/full/caac.20073v1>.
2. Johnson LG, Madeleine MM, Newcomer LM, et al. Anal cancer incidence and survival: the surveillance, epidemiology, and end results experience, 1973-2000. *Cancer* 2004;101:281-288. Available at: <http://www.ncbi.nlm.nih.gov/pubmed/15241824>.
3. Daling JR, Madeleine MM, Johnson LG, et al. Human papillomavirus, smoking, and sexual practices in the etiology of anal cancer. *Cancer* 2004;101:270-280. Available at: <http://www.ncbi.nlm.nih.gov/pubmed/15241823>.
4. Frisch M, Glimelius B, van den Brule AJ, et al. Sexually transmitted infection as a cause of anal cancer. *N Engl J Med* 1997;337:1350-1358. Available at: <http://www.ncbi.nlm.nih.gov/pubmed/9358129>.
5. Jimenez W, Paszat L, Kupets R, et al. Presumed previous human papillomavirus (HPV) related gynecological cancer in women diagnosed with anal cancer in the province of Ontario. *Gynecol Oncol* 2009;114:395-398. Available at: <http://www.ncbi.nlm.nih.gov/pubmed/19501390>.
6. Ryan DP, Compton CC, Mayer RJ. Carcinoma of the anal canal. *N Engl J Med* 2000;342:792-800. Available at: <http://www.ncbi.nlm.nih.gov/pubmed/10717015>.
7. Sunesen KG, Norgaard M, Thorlacius-Ussing O, Laurberg S. Immunosuppressive disorders and risk of anal squamous cell carcinoma: a nationwide cohort study in Denmark, 1978-2005. *Int J Cancer* 2010;127:675-684. Available at: <http://www.ncbi.nlm.nih.gov/pubmed/19960431>.
8. Frisch M, Biggar RJ, Goedert JJ. Human papillomavirus-associated cancers in patients with human immunodeficiency virus infection and acquired immunodeficiency syndrome. *J Natl Cancer Inst* 2000;92:1500-1510. Available at: <http://www.ncbi.nlm.nih.gov/pubmed/10995805>.
9. Uronis HE, Bendell JC. Anal cancer: an overview. *Oncologist* 2007;12:524-534. Available at: <http://www.ncbi.nlm.nih.gov/pubmed/17522240>.
10. De Vuyst H, Clifford GM, Nascimento MC, et al. Prevalence and type distribution of human papillomavirus in carcinoma and intraepithelial neoplasia of the vulva, vagina and anus: a meta-analysis. *Int J Cancer* 2009;124:1626-1636. Available at: <http://www.ncbi.nlm.nih.gov/pubmed/19115209>.
11. Hoots BE, Palefsky JM, Pimenta JM, Smith JS. Human papillomavirus type distribution in anal cancer and anal intraepithelial lesions. *Int J Cancer* 2009;124:2375-2383. Available at: <http://www.ncbi.nlm.nih.gov/pubmed/19189402>.
12. Palefsky JM, Holly EA, Ralston ML, Jay N. Prevalence and risk factors for human papillomavirus infection of the anal canal in human immunodeficiency virus (HIV)-positive and HIV-negative homosexual men. *J Infect Dis* 1998;177:361-367. Available at: <http://www.ncbi.nlm.nih.gov/pubmed/9466522>.
13. Patel HS, Silver AR, Northover JM. Anal cancer in renal transplant patients. *Int J Colorectal Dis* 2007;22:1-5. Available at: <http://www.ncbi.nlm.nih.gov/pubmed/16133005>.
14. Patel P, Hanson DL, Sullivan PS, et al. Incidence of types of cancer among HIV-infected persons compared with the general population in the United States, 1992-2003. *Ann Intern Med* 2008;148:728-736. Available at: <http://www.ncbi.nlm.nih.gov/pubmed/18490686>.
15. Cummings BJ, Ajani JA, Swallow CJ. Cancer of the anal region. In: DeVita Jr. VT, Lawrence TS, Rosenberg SA, et al., eds. *Cancer: Principles & Practice of Oncology*, Eighth Edition. Philadelphia, PA: Lippincott, Williams & Wilkins; 2008.

16. Nivatvongs S, Stern HS, Fryd DS. The length of the anal canal. *Dis Colon Rectum* 1981;24:600-601. Available at: <http://www.ncbi.nlm.nih.gov/pubmed/7318624>.
17. Rickert RR, Compton CC. Protocol for the examination of specimens from patients with carcinomas of the anus and anal canal: a basis for checklists. *Cancer Committee of the College of American Pathologists. Arch Pathol Lab Med* 2000;124:21-25. Available at: <http://www.ncbi.nlm.nih.gov/pubmed/10629126>.
18. Edge SBB, D.R.; Compton, C.C.; Fritz, A.G.; Greene, F.L.; Trotti, A., ed *AJCC Cancer Staging Manual* (ed 7th Edition). New York: Springer; 2010.
19. Jass JR, Sobin LH. *Histological Typing of Intestinal Tumours*: Springer-Verlag Berlin Heidelberg; 1989.
20. Fenger C, Frisch M, Marti MC, Parc R. Tumours of the anal canal. In: Hamilton SR, Aaltonen LA, eds. *WHO Classification of Tumours, Volume 2: Pathology and Genetics. Tumours of the Digestive System*. Lyon: IARC Press; 2000:145-155.
21. Welton ML, Lambert R, Bosman FT. Tumours of the Anal Canal. In: Bosman FT, Carneiro, F., Hruban, R. H., Theise, N.D., ed. *WHO Classification of Tumours of the Digestive System*. Lyon: IARC; 2010:183-193.
22. Fenger C. Prognostic factors in anal carcinoma. *Pathology* 2002;34:573-578. Available at: <http://www.ncbi.nlm.nih.gov/pubmed/12555997>.
23. Oliver GC, Labow SB. Neoplasms of the anus. *Surg Clin North Am* 1994;74:1475-1490. Available at: <http://www.ncbi.nlm.nih.gov/pubmed/7985077>.
24. Altekruse SF, Kosary CL, Krapcho M, et al., eds. *SEER Cancer Statistics Review, 1975-2007*. Bethesda, MD: National Cancer Institute;
25. Wade DS, Herrera L, Castillo NB, Petrelli NJ. Metastases to the lymph nodes in epidermoid carcinoma of the anal canal studied by a clearing technique. *Surg Gynecol Obstet* 1989;169:238-242. Available at: <http://www.ncbi.nlm.nih.gov/pubmed/2672386>.
26. Gerard JP, Chapet O, Samiei F, et al. Management of inguinal lymph node metastases in patients with carcinoma of the anal canal: experience in a series of 270 patients treated in Lyon and review of the literature. *Cancer* 2001;92:77-84. Available at: <http://www.ncbi.nlm.nih.gov/pubmed/11443612>.
27. Cotter SE, Grigsby PW, Siegel BA, et al. FDG-PET/CT in the evaluation of anal carcinoma. *Int J Radiat Oncol Biol Phys* 2006;65:720-725. Available at: <http://www.ncbi.nlm.nih.gov/pubmed/16626889>.
28. Pepek JM, Willett CG, Czito BG. Radiation therapy advances for treatment of anal cancer. *J Natl Compr Canc Netw* 2010;8:123-129. Available at: <http://www.ncbi.nlm.nih.gov/pubmed/20064294>.
29. Trautmann TG, Zuger JH. Positron Emission Tomography for pretreatment staging and posttreatment evaluation in cancer of the anal canal. *Mol Imaging Biol* 2005;7:309-313. Available at: <http://www.ncbi.nlm.nih.gov/pubmed/16028002>.
30. Nigro ND, Vaitkevicius VK, Considine B. Combined therapy for cancer of the anal canal: a preliminary report. *Dis Colon Rectum* 1974;17:354-356. Available at: <http://www.ncbi.nlm.nih.gov/pubmed/4830803>.
31. Cummings BJ, Keane TJ, O'Sullivan B, et al. Epidermoid anal cancer: treatment by radiation alone or by radiation and 5-fluorouracil with and without mitomycin C. *Int J Radiat Oncol Biol Phys* 1991;21:1115-1125. Available at: <http://www.ncbi.nlm.nih.gov/pubmed/1938508>.
32. Papillon J, Chassard JL. Respective roles of radiotherapy and surgery in the management of epidermoid carcinoma of the anal



margin. Series of 57 patients. *Dis Colon Rectum* 1992;35:422-429. Available at: <http://www.ncbi.nlm.nih.gov/pubmed/1568392>.

33. Bartelink H, Roelofsen F, Eschwege F, et al. Concomitant radiotherapy and chemotherapy is superior to radiotherapy alone in the treatment of locally advanced anal cancer: results of a phase III randomized trial of the European Organization for Research and Treatment of Cancer Radiotherapy and Gastrointestinal Cooperative Groups. *J Clin Oncol* 1997;15:2040-2049. Available at: <http://www.ncbi.nlm.nih.gov/pubmed/9164216>.

34. Epidermoid anal cancer: results from the UKCCCR randomised trial of radiotherapy alone versus radiotherapy, 5-fluorouracil, and mitomycin. UKCCCR Anal Cancer Trial Working Party. UK Co-ordinating Committee on Cancer Research. *Lancet* 1996;348:1049-1054. Available at: <http://www.ncbi.nlm.nih.gov/pubmed/8874455>.

35. Northover J, Glynne-Jones R, Sebag-Montefiore D, et al. Chemoradiation for the treatment of epidermoid anal cancer: 13-year follow-up of the first randomised UKCCCR Anal Cancer Trial (ACT I). *Br J Cancer* 2010;102:1123-1128. Available at: <http://www.ncbi.nlm.nih.gov/pubmed/20354531>.

36. Flam M, John M, Pajak TF, et al. Role of mitomycin in combination with fluorouracil and radiotherapy, and of salvage chemoradiation in the definitive nonsurgical treatment of epidermoid carcinoma of the anal canal: results of a phase III randomized intergroup study. *J Clin Oncol* 1996;14:2527-2539. Available at: <http://www.ncbi.nlm.nih.gov/pubmed/8823332>.

37. Crehange G, Bosset M, Lorcher F, et al. Combining cisplatin and mitomycin with radiotherapy in anal carcinoma. *Dis Colon Rectum* 2007;50:43-49. Available at: <http://www.ncbi.nlm.nih.gov/pubmed/17089083>.

38. Ajani JA, Winter KA, Gunderson LL, et al. Fluorouracil, mitomycin, and radiotherapy vs fluorouracil, cisplatin, and radiotherapy for carcinoma of the anal canal: a randomized controlled trial. *JAMA*

2008;299:1914-1921. Available at: <http://www.ncbi.nlm.nih.gov/pubmed/18430910>.

39. Czito BG, Willett CG. Current management of anal canal cancer. *Curr Oncol Rep* 2009;11:186-192. Available at: <http://www.ncbi.nlm.nih.gov/pubmed/19336010>.

40. Eng C, Crane CH, Rodriguez-Bigas MA. Should cisplatin be avoided in the treatment of locally advanced squamous cell carcinoma of the anal canal? *Nat Clin Pract Gastroenterol Hepatol* 2009;6:16-17. Available at: <http://www.ncbi.nlm.nih.gov/pubmed/19047998>.

41. Ajani JA, Winter KA, Gunderson LL, et al. US intergroup anal carcinoma trial: tumor diameter predicts for colostomy. *J Clin Oncol* 2009;27:1116-1121. Available at: <http://www.ncbi.nlm.nih.gov/pubmed/19139424>.

42. James R, Wan S, Glynne-Jones R, et al. A randomized trial of chemoradiation using mitomycin or cisplatin, with or without maintenance cisplatin/5FU in squamous cell carcinoma of the anus (ACT II) [abstract]. *J Clin Oncol* 2009;27 (June 20 suppl):LBA4009. Available at: <http://meeting.ascopubs.org/cgi/content/abstract/27/18S/LBA4009>.

43. Ortholan C, Ramaioli A, Peiffert D, et al. Anal canal carcinoma: early-stage tumors < or =10 mm (T1 or Tis): therapeutic options and original pattern of local failure after radiotherapy. *Int J Radiat Oncol Biol Phys* 2005;62:479-485. Available at: <http://www.ncbi.nlm.nih.gov/pubmed/15890590>.

44. Ferrigno R, Nakamura RA, Dos Santos Novaes PER, et al. Radiochemotherapy in the conservative treatment of anal canal carcinoma: retrospective analysis of results and radiation dose effectiveness. *Int J Radiat Oncol Biol Phys* 2005;61:1136-1142. Available at: <http://www.ncbi.nlm.nih.gov/pubmed/15752894>.

45. Huang K, Haas-Kogan D, Weinberg V, Krieg R. Higher radiation dose with a shorter treatment duration improves outcome for locally

advanced carcinoma of anal canal. *World J Gastroenterol* 2007;13:895-900. Available at: <http://www.ncbi.nlm.nih.gov/pubmed/17352019>.

46. Konski A, Garcia M, Jr., John M, et al. Evaluation of planned treatment breaks during radiation therapy for anal cancer: update of RTOG 92-08. *Int J Radiat Oncol Biol Phys* 2008;72:114-118. Available at: <http://www.ncbi.nlm.nih.gov/pubmed/18472363>.

47. Ben-Josef E, Moughan J, Ajani JA, et al. Impact of Overall Treatment Time on Survival and Local Control in Patients With Anal Cancer: A Pooled Data Analysis of Radiation Therapy Oncology Group Trials 87-04 and 98-11. *J Clin Oncol* 2010;28:5061-5066. Available at: <http://www.ncbi.nlm.nih.gov/pubmed/20956625>.

48. Graf R, Wust P, Hildebrandt B, et al. Impact of overall treatment time on local control of anal cancer treated with radiochemotherapy. *Oncology* 2003;65:14-22. Available at: <http://www.ncbi.nlm.nih.gov/pubmed/12837978>.

49. Roohipour R, Patil S, Goodman KA, et al. Squamous-cell carcinoma of the anal canal: predictors of treatment outcome. *Dis Colon Rectum* 2008;51:147-153. Available at: <http://www.ncbi.nlm.nih.gov/pubmed/18180997>.

50. Allal AS, Sprangers MA, Laurencet F, et al. Assessment of long-term quality of life in patients with anal carcinomas treated by radiotherapy with or without chemotherapy. *Br J Cancer* 1999;80:1588-1594. Available at: <http://www.ncbi.nlm.nih.gov/pubmed/10408404>.

51. de Bree E, van Ruth S, Dewit LGH, Zoetmulder FAN. High risk of colostomy with primary radiotherapy for anal cancer. *Ann Surg Oncol* 2007;14:100-108. Available at: <http://www.ncbi.nlm.nih.gov/pubmed/17066231>.

52. Baxter NN, Habermann EB, Tepper JE, et al. Risk of pelvic fractures in older women following pelvic irradiation. *JAMA* 2005;294:2587-2593. Available at: <http://www.ncbi.nlm.nih.gov/pubmed/16304072>.

53. Chen YJ, Liu A, Tsai PT, et al. Organ sparing by conformal avoidance intensity-modulated radiation therapy for anal cancer: dosimetric evaluation of coverage of pelvis and inguinal/femoral nodes. *Int J Radiat Oncol Biol Phys* 2005;63:274-281. Available at: <http://www.ncbi.nlm.nih.gov/pubmed/16111597>.

54. Kachnic LA, Tsai HK, Coen JJ, et al. Dose-painted Intensity-modulated Radiation Therapy for Anal Cancer: A Multi-institutional Report of Acute Toxicity and Response to Therapy. *Int J Radiat Oncol Biol Phys* 2010. Available at: <http://www.ncbi.nlm.nih.gov/pubmed/21095071>.

55. Lin A, Ben-Josef E. Intensity-modulated radiation therapy for the treatment of anal cancer. *Clin Colorectal Cancer* 2007;6:716-719. Available at: <http://www.ncbi.nlm.nih.gov/pubmed/18039425>.

56. Milano MT, Jani AB, Farrey KJ, et al. Intensity-modulated radiation therapy (IMRT) in the treatment of anal cancer: toxicity and clinical outcome. *Int J Radiat Oncol Biol Phys* 2005;63:354-361. Available at: <http://www.ncbi.nlm.nih.gov/pubmed/16168830>.

57. Salama JK, Mell LK, Schomas DA, et al. Concurrent chemotherapy and intensity-modulated radiation therapy for anal canal cancer patients: a multicenter experience. *J Clin Oncol* 2007;25:4581-4586. Available at: <http://www.ncbi.nlm.nih.gov/pubmed/17925552>.

58. Hong TS, Tsai HK, Coen J, et al. Dose-painted intensity-modulated radiation therapy for anal cancer: A multi-institutional report of acute toxicity and response to therapy [abstract]. *J Clin Oncol* 2010;28 (May 20 suppl):4144. Available at: http://meeting.ascopubs.org/cgi/content/abstract/28/15_suppl/4144.

59. Kachnic LA, Winter KA, Myerson RJ, et al. RTOG 0529: A phase II study of dose-painted IMRT (DP-IMRT), 5-fluorouracil, and mitomycin-C for the reduction of acute morbidity in anal cancer [abstract]. 2010 Gastrointestinal Cancers Symposium 2010:405. Available at: http://www.asco.org/ascov2/Meetings/Abstracts?&vmview=abst_detail_view&confID=72&abstractID=1606.

60. Myerson RJ, Garofalo MC, El Naqa I, et al. Elective clinical target volumes for conformal therapy in anorectal cancer: a radiation therapy oncology group consensus panel contouring atlas. *Int J Radiat Oncol Biol Phys* 2009;74:824-830. Available at: <http://www.ncbi.nlm.nih.gov/pubmed/19117696>.
61. Fraunholz I, Weiss C, Eberlein K, et al. Concurrent chemoradiotherapy with 5-fluorouracil and mitomycin C for invasive anal carcinoma in human immunodeficiency virus-positive patients receiving highly active antiretroviral therapy. *Int J Radiat Oncol Biol Phys* 2010;76:1425-1432. Available at: <http://www.ncbi.nlm.nih.gov/pubmed/19744801>.
62. Hoffman R, Welton ML, Klencke B, et al. The significance of pretreatment CD4 count on the outcome and treatment tolerance of HIV-positive patients with anal cancer. *Int J Radiat Oncol Biol Phys* 1999;44:127-131. Available at: <http://www.ncbi.nlm.nih.gov/pubmed/10219805>.
63. Chiao EY, Giordano TP, Richardson P, El-Serag HB. Human immunodeficiency virus-associated squamous cell cancer of the anus: epidemiology and outcomes in the highly active antiretroviral therapy era. *J Clin Oncol* 2008;26:474-479. Available at: <http://www.ncbi.nlm.nih.gov/pubmed/18202423>.
64. Seo Y, Kinsella MT, Reynolds HL, et al. Outcomes of chemoradiotherapy with 5-Fluorouracil and mitomycin C for anal cancer in immunocompetent versus immunodeficient patients. *Int J Radiat Oncol Biol Phys* 2009;75:143-149. Available at: <http://www.ncbi.nlm.nih.gov/pubmed/19203845>.
65. Oehler-Janne C, Huguet F, Provencher S, et al. HIV-specific differences in outcome of squamous cell carcinoma of the anal canal: a multicentric cohort study of HIV-positive patients receiving highly active antiretroviral therapy. *J Clin Oncol* 2008;26:2550-2557. Available at: <http://www.ncbi.nlm.nih.gov/pubmed/18427149>.
66. Klencke BJ, Palefsky JM. Anal cancer: an HIV-associated cancer. *Hematol Oncol Clin North Am* 2003;17:859-872. Available at: <http://www.ncbi.nlm.nih.gov/pubmed/12852659>.
67. Faivre C, Rougier P, Ducreux M, et al. [5-fluorouracil and cisplatin combination chemotherapy for metastatic squamous-cell anal cancer]. *Bull Cancer* 1999;86:861-865. Available at: <http://www.ncbi.nlm.nih.gov/pubmed/10572237>.
68. Schiller DE, Cummings BJ, Rai S, et al. Outcomes of salvage surgery for squamous cell carcinoma of the anal canal. *Ann Surg Oncol* 2007;14:2780-2789. Available at: <http://www.ncbi.nlm.nih.gov/pubmed/17638059>.
69. Mullen JT, Rodriguez-Bigas MA, Chang GJ, et al. Results of surgical salvage after failed chemoradiation therapy for epidermoid carcinoma of the anal canal. *Ann Surg Oncol* 2007;14:478-483. Available at: <http://www.ncbi.nlm.nih.gov/pubmed/17103253>.
70. Das P, Bhatia S, Eng C, et al. Predictors and patterns of recurrence after definitive chemoradiation for anal cancer. *Int J Radiat Oncol Biol Phys* 2007;68:794-800. Available at: <http://www.ncbi.nlm.nih.gov/pubmed/17379452>.
71. Allal AS, Laurencet FM, Reymond MA, et al. Effectiveness of surgical salvage therapy for patients with locally uncontrolled anal carcinoma after sphincter-conserving treatment. *Cancer* 1999;86:405-409. Available at: <http://www.ncbi.nlm.nih.gov/pubmed/10430247>.
72. Ellenhorn JD, Enker WE, Quan SH. Salvage abdominoperineal resection following combined chemotherapy and radiotherapy for epidermoid carcinoma of the anus. *Ann Surg Oncol* 1994;1:105-110. Available at: <http://www.ncbi.nlm.nih.gov/pubmed/7834434>.
73. Nilsson PJ, Svensson C, Goldman S, Glimelius B. Salvage abdominoperineal resection in anal epidermoid cancer. *Br J Surg* 2002;89:1425-1429. Available at: <http://www.ncbi.nlm.nih.gov/pubmed/12390386>.



74. Chessin DB, Hartley J, Cohen AM, et al. Rectus flap reconstruction decreases perineal wound complications after pelvic chemoradiation and surgery: a cohort study. *Ann Surg Oncol* 2005;12:104-110. Available at: <http://www.ncbi.nlm.nih.gov/pubmed/15827789>.

75. Cummings BJ. Metastatic anal cancer: the search for cure. *Onkologie* 2006;29:5-6. Available at: <http://www.ncbi.nlm.nih.gov/pubmed/16514247>.

76. Ajani JA, Carrasco CH, Jackson DE, Wallace S. Combination of cisplatin plus fluoropyrimidine chemotherapy effective against liver metastases from carcinoma of the anal canal. *Am J Med* 1989;87:221-224. Available at: <http://www.ncbi.nlm.nih.gov/pubmed/2527006>.

77. Jaiyesimi IA, Pazdur R. Cisplatin and 5-fluorouracil as salvage therapy for recurrent metastatic squamous cell carcinoma of the anal canal. *Am J Clin Oncol* 1993;16:536-540. Available at: <http://www.ncbi.nlm.nih.gov/pubmed/8256774>.

Discussion
update in
progress